

## Creating global awareness of re-emerging monkeypox disease for healthcare workers

O. M. Cole-Adeife<sup>1\*</sup>, A. O. Akinkugbe<sup>2</sup>, O. Sodipo<sup>1</sup>, S. O. Oiwoh<sup>3</sup>

<sup>1</sup> Lagos State University Teaching Hospital, Ikeja, Lagos, Nigeria.

<sup>2</sup> College of Medicine, University of Lagos, Lagos, Nigeria.

<sup>3</sup> Irrua Specialist Teaching Hospital Irrua Edo State Nigeria.

\*Corresponding author: [ocole@lasuth.org.ng](mailto:ocole@lasuth.org.ng)

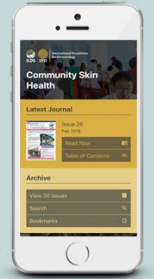
**Conflict of interests:** None.

**Key words:** Monkeypox, re-emerging pathogens, infectious diseases.

### Community Skin Health App

The CSH App is available on both iOS and Android.

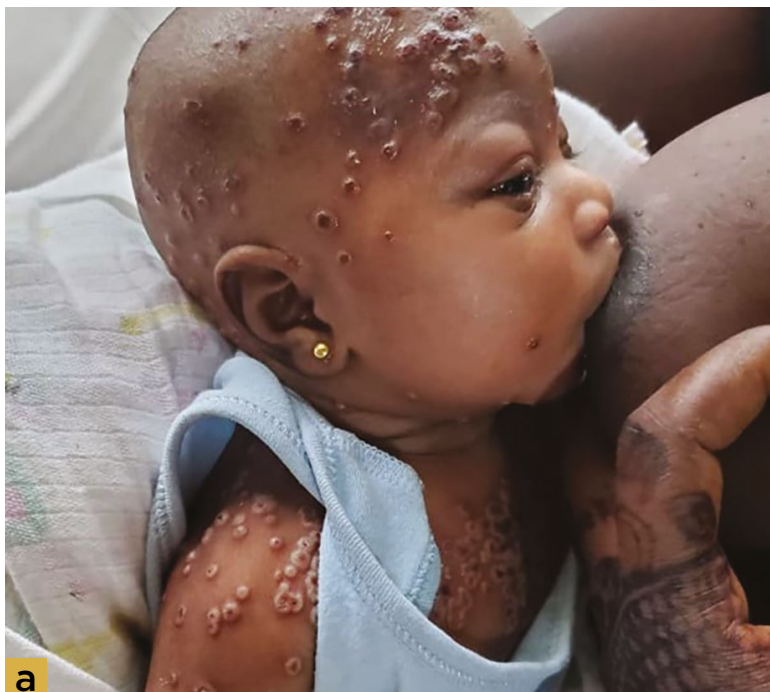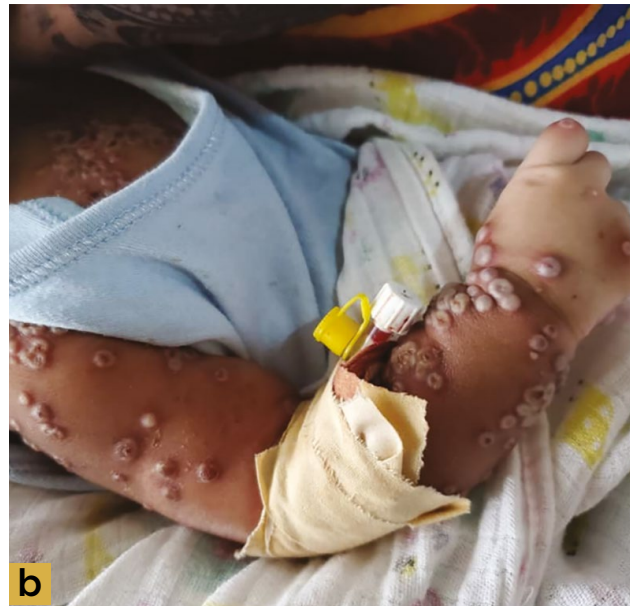You can now have every issue at your fingertips, search the comprehensive archive for hot topics, bookmark your favourite articles and automatically get the latest issue delivered straight to your phone.



### Abstract

Monkeypox is a re-emerging infectious skin disease of global health concern caused by the monkeypox virus. Monkeypox virus disease occurs primarily in Central and West Africa but continues to be exported to other regions of the world with a recent ongoing multicountry outbreak in non-endemic countries. The exponential increase in monkeypox cases in the past 20 years has been linked to the cessation of smallpox vaccination in 1980, which was also protective against monkeypox.

This review is an update for health workers on human monkeypox virus disease, highlighting the modes of transmission and clinical course of the disease, emphasizing the skin manifestations and differential diagnoses.



**Fig 1. (a) and (b)** Extensive monkeypox lesions. Reproduced with kind permission of Dr M. Agyei, Komfo Anokye Teaching Hospital (KATH), Kumasi, Ghana.

### Contents

- 1** **Creating global awareness of re-emerging monkeypox disease for healthcare workers**  
O. M. Cole-Adeife, A. O. Akinkugbe, O. Sodipo and S. O. Oiwoh
- 8** **Guide to diagnosis and management of leprosy**  
Marlous L. Grijzen and Ben Naafs
- 13** **Journal Club: Treatment of pyogenic granuloma with salt therapy: an effective approach**  
Ruth Lawless and Anna Ascott
- 14** **Atypical clinical presentation of dermatophytosis in a child: a reflection of topical steroid misuse**  
Durga Satheesh and Ramesh M. Bhat

## Key learning points:

- Monkeypox is a global re-emerging viral infectious disease.
- It is transmitted to humans through close contact with an infected person or animal; or contaminated material.
- It is usually self-limiting, with symptoms lasting 3–4 weeks.
- The skin is important for early and prompt recognition of monkeypox infection.
- A rash develops within a few days of the infection, often beginning on the face and spreads to other parts of the body including the palms and the soles.
- Awareness among healthcare workers globally is of utmost importance.

## Introduction

Monkeypox is a re-emerging infectious skin disease caused by a DNA virus member of the *Orthopoxvirus* genus in the family *Poxviridae* – the same family of viruses as cowpox and smallpox.<sup>1–3</sup> The disease is a viral zoonosis with symptoms similar to smallpox, although usually clinically less severe.<sup>1,4</sup>

Monkeypox disease occurs primarily in the tropical rainforest areas of Central and West Africa but continues to be exported to other regions.<sup>1,3,4</sup> There are two genotypes or clades of monkeypox – the West African clade, which typically causes milder clinical disease, and the Congo Basin clade, which is associated with a more severe clinical course and higher mortality.<sup>1–4</sup>

## Epidemiology

The monkeypox virus was first discovered in monkeys under investigation in a research laboratory in Denmark in 1958 and the first reported infection in a human was in the Democratic Republic of the Congo (DRC) in 1970.<sup>3,4</sup> Since then, several thousand human cases of monkeypox have been confirmed in 11 African countries, including the DRC, Nigeria, Sierra Leone, Côte d'Ivoire, Gabon, Cameroon, Central African Republic and South Sudan.<sup>3,4</sup> A 20-fold increase in cases has been observed over the past two decades.<sup>4–6</sup> Since 2001, the DRC reported an estimated 3000 cases per year, and Nigeria experienced an outbreak of human monkeypox between 2017 and 2019, after a 39-year absence of cases.<sup>2,4,5</sup> The re-emergence of the disease is linked to the global discontinuation of the smallpox vaccine in 1980, which also offered protection against other orthopoxviruses like monkeypox.<sup>1,3,5</sup> Human monkeypox is commoner in males and the median age of people with the disease is about 30 years.<sup>2,4,5</sup>

Human monkeypox has occasionally been exported out of Africa. In 2003 there was an outbreak of 47 cases of human monkeypox in the USA linked to the pet trade of some animals from Ghana, and there have also been sporadic cases reported in the UK, USA, Singapore and Israel in the past 4 years in people with recent travel history to West Africa.<sup>4,6</sup> More recently, an unexpectedly large outbreak of over 100

cases has been reported in Europe, the USA, Canada and Australia at the time of submission of this article.<sup>7</sup> It has been described as rare and unusual as most of the cases in the current outbreak have not been linked to recent travel to Africa or contact with anyone known to have travelled to countries where monkeypox is endemic.<sup>7</sup>

**Animal-to-human transmission:** The reservoir and mode of transmission of monkeypox have not been fully established. However, it can be transmitted via animal-to-human contact (direct and indirect) with infected body fluids (blood and secretions from the eyes, mouth or skin lesions) and by intradermal inoculation from bites and scratches sustained during hunting.<sup>1–4</sup> Even though it is called monkeypox, the likely reservoirs include Gambian rats, bush rats and squirrels, although prairie dogs and monkeys of various species have also been documented to be carriers of the virus.<sup>3–5</sup> Another risk factor identified is the consumption of inadequately cooked meat from infected animals.<sup>6</sup>

The virus is presumed to enter the body through broken skin (intradermal inoculation), the respiratory tract or the mucous membranes (eyes, nose or mouth).<sup>1,3,4</sup> The natural history and pathogenesis of monkeypox in animals and humans requires further study as specific pathogenetic mechanisms remain undefined.<sup>3–5</sup>

**Human-to-human transmission:** The risk of human-to-human transmission of the monkeypox virus is low but can occur in someone who has close contact with an infected individual.<sup>2–4</sup> The Congo Basin clade is associated with a higher potential for human-to-human transmission compared with the West African clade.<sup>1,3,4</sup> Routes of entry are respiratory droplets and direct contact with the infected secretions or skin lesions of patients with broken skin (even if not visible) or mucous membranes (eyes, nose or mouth).<sup>1,4,6</sup> Sexual transmission (including men who have sex with men) is also possible from close contact with genital lesions.<sup>2,3,8</sup> Indirect contact with objects recently contaminated by a patient's body fluids or lesions (such as clothing or bed linen) can also lead to infection.<sup>3,4</sup> Hospital-acquired infections have been reported in Nigeria, the DRC and the UK.<sup>4,6</sup>

## Clinical features

The clinical manifestations of monkeypox usually develop within 5–21 days of infection or initial exposure to the virus.<sup>1,2</sup> It is often a mild, self-limiting illness with spontaneous and complete recovery within 3–4 weeks of onset.<sup>1,2</sup> However, severe illness does occur and can sometimes result in death.<sup>1,2,6</sup>

Clinical symptoms can be divided into two periods.<sup>1,6</sup>

- **The invasion or prodromal period** (0–5 days) that presents with fever, headache, back pain, myalgia and malaise (flu-like symptoms).
- **The skin eruption period** that usually begins within 1–3 days of the appearance of fever and lasts approximately 2 weeks or more.

The evolution of the rash, which occurs over 10 days, progresses through the following stages:<sup>1,6</sup>

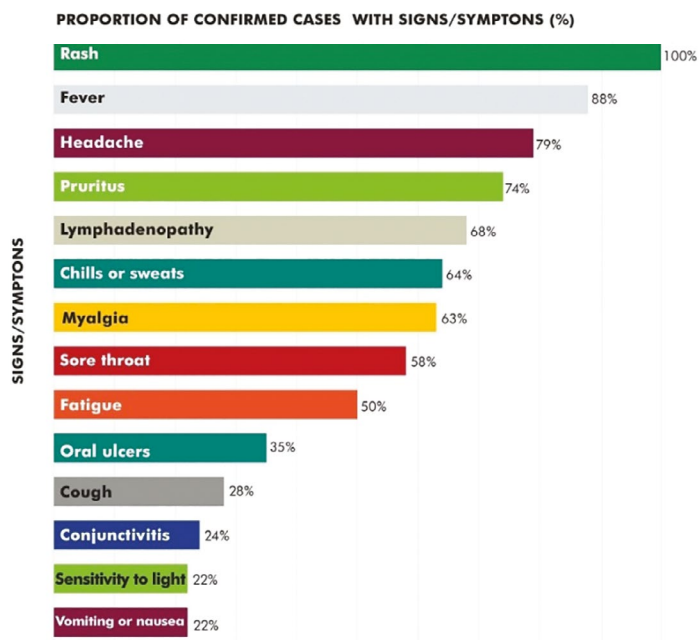
- macules (lesions with a flat base);

- vesicles (small fluid-filled blisters);
- pustules (pus-containing lesions);
- crust (dried blisters).

Patients are usually infective until the crusts and scabs clear.<sup>1,6</sup>

The skin lesions are often associated with pruritus and lymphadenopathy, which can be localized or generalized.<sup>2,4</sup> Skin eruptions tend to be more concentrated on the face and extremities than on the trunk. The rashes appear in various stages, often beginning on the face and then spreading to the extremities and trunk. The face (95% of cases) and palms and soles (75% of cases) are most affected.<sup>2,4,6</sup> There may also be mucosal (conjunctival, nasal and oral) involvement.<sup>6</sup> The presence of lymphadenopathy is a key symptom differentiating monkeypox from chickenpox and smallpox.<sup>2,6</sup>

The frequency of symptoms also varies. The Nigerian Centre for Disease Control (NCDC) reported skin lesions in all confirmed cases (100%), followed by fever, headache, pruritus and lymphadenopathy in 88%, 79%, 74% and 68% of cases, respectively<sup>6</sup> (Figure 2).



**Fig 2.** Frequency of signs and symptoms among Nigerian confirmed monkeypox cases (Sept 2017 to Sept 2018).<sup>6</sup> Reproduced with permission of the Nigerian Centre for Disease Control.

Severe clinical presentations occur in children and in patients with coexisting HIV infection or other immunosuppressive conditions.<sup>2,5,6</sup>

Appropriate and prompt diagnosis, classification, isolation of patients and disease notification are key in managing human monkeypox infection. The NCDC has developed case definitions for appropriate management, risk communication and surveillance<sup>6</sup> (Table 1).

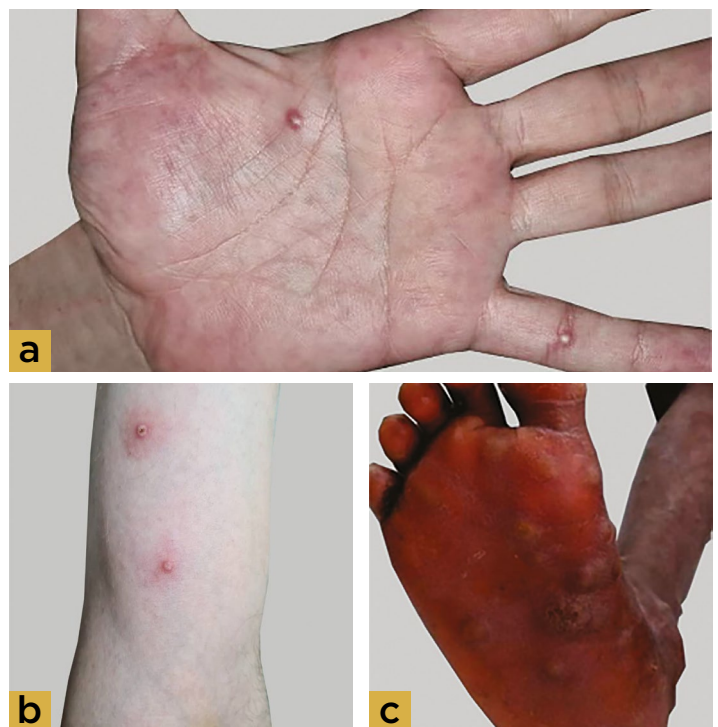Clinical presentations of monkeypox infection at various stages of the disease and in different parts of the body are seen in Figures 3–7.

## Diagnosis

The monkeypox rash can be clinically indistinguishable from severe chickenpox or smallpox.<sup>5</sup> Depending on the stage of the

**Table 1**  
Case definitions for human monkeypox virus disease<sup>2,6,9</sup>

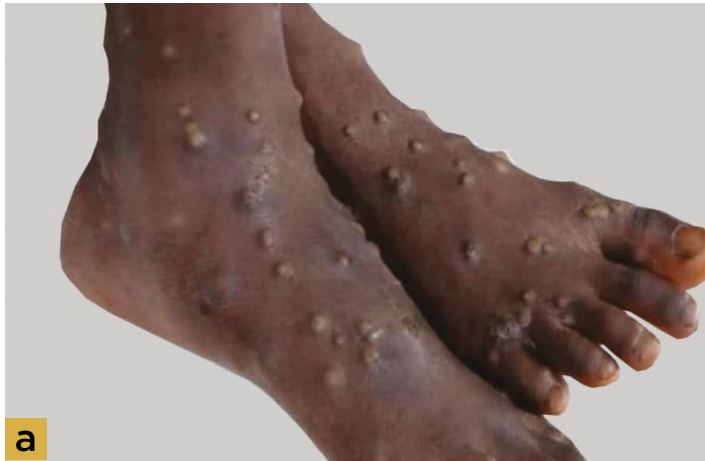Type	Definition
Suspected case	Any person presenting with a history of sudden onset fever (>38°C) followed by a vesiculopustular rash occurring mostly on the face, palms and soles of the feet
Confirmed case	A suspected case with laboratory confirmation (i.e. viral identification via real-time polymerase chain reaction [PCR], IgM antibody detection or viral isolation)
Probable case	A suspected case in whom laboratory testing could not be done but who could be epidemiologically linked with a confirmed case
Contact person	A person who has no symptoms but had been in physical contact with a suspected or confirmed case or with body fluids (skin secretions, oral secretions, urine, faeces, vomitus or blood) of a case in the past 21 days
Primary case	A suspected or confirmed case without prior contact with an infected patient (confirmed case) within 21 days preceding the infection onset
Secondary case	A suspected or confirmed case who had been in contact with a confirmed case within 21 days preceding the infection onset



**Fig 3.** (a) Erythematous papules on the palm; (b) umbilicated vesiculopustular lesions on the forearm with surrounding erythema of the skin ((a) and (b) courtesy of Dr O. Cole-Adeife); (c) pox-like papulopustular lesions on the sole (Courtesy of Dr J. Agarry).

Continued overleaf...

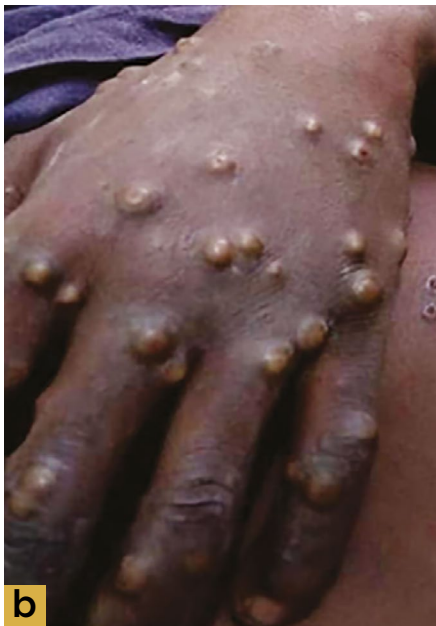



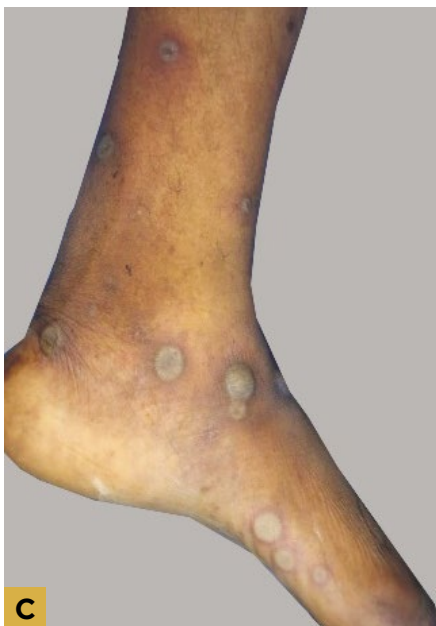**a**

skin lesions, other possible differentials include impetigo (in children), syphilis, molluscum contagiosum, scabies, drug eruptions, eczema herpeticum, disseminated herpes, disseminated histoplasmosis, and hand, foot and mouth disease, among others.<sup>6</sup> Thus, a definite diagnosis of monkeypox cannot be based on clinical findings alone. It is recommended that blood and skin (crusts or scab) samples should be sent for diagnostic testing.<sup>1,5,6</sup>

The recommended specimen type for laboratory confirmation of monkeypox is skin lesional material, including swabs of lesion surface and/or exudate.<sup>1,6</sup> Two samples from two different sites should be taken from the skin. These can be taken from the fluid or base of the vesicles, pustules and dry crusts and stored in ziplock bags without viral transport

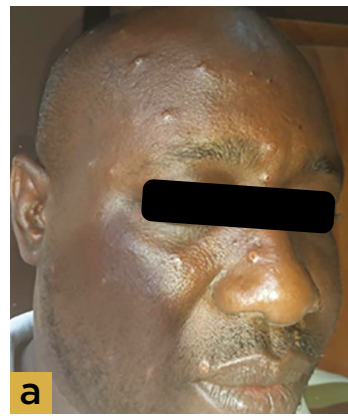

**b**

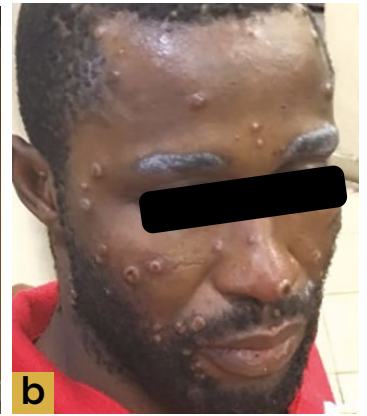

**c**

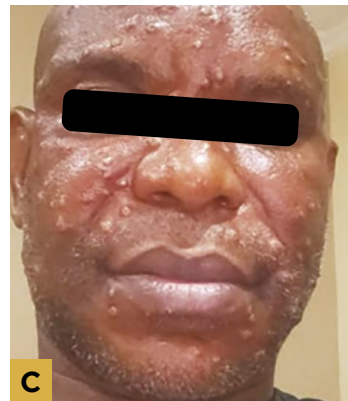**Fig 4. (a-c)** Multiple 'pox-like' papulopustular lesions on the feet and the dorsum of the hand. **(a)** and **(b)** courtesy of Dr J. Agarry; **(c)** courtesy of Dr A. O. Akinkugbe.



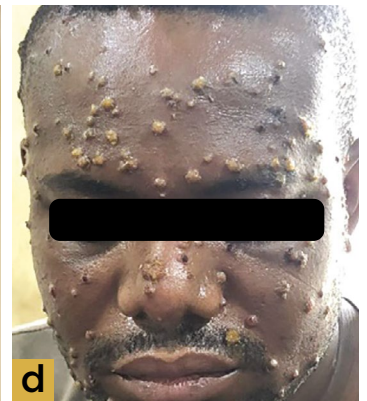**a**



**b**



**c**



**d**

**Fig 5. (a-d)** Papular and vesiculo-pustular lesions on the face at different stages of the infection. **(a)** Dome-shaped papules (courtesy of Dr A. O. Akinkugbe); **(b)** pox-like umbilicated papules with crusting (courtesy of Dr O. Akinsiku); **(c)** papulopustular lesions with umbilication (courtesy of Dr O. Cole-Adeife); **(d)** crusted, pustular lesions (courtesy of Dr I. Akwara).

medium.<sup>3,6</sup> Polymerase chain reaction (PCR) is the preferred laboratory test, given its accuracy and sensitivity. PCR for both monkeypox virus and varicella zoster virus should be undertaken for all samples as varicella zoster virus is a common differential diagnosis.<sup>3,5</sup> In an outbreak in the Central African Republic in 2016, 45% of suspected monkeypox cases were varicella zoster virus-positive and monkeypox virus-negative.<sup>9</sup>

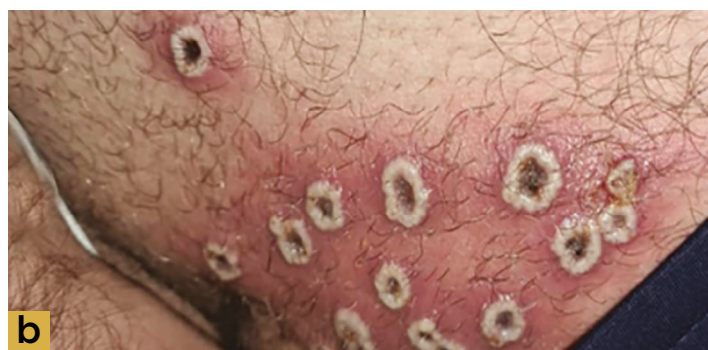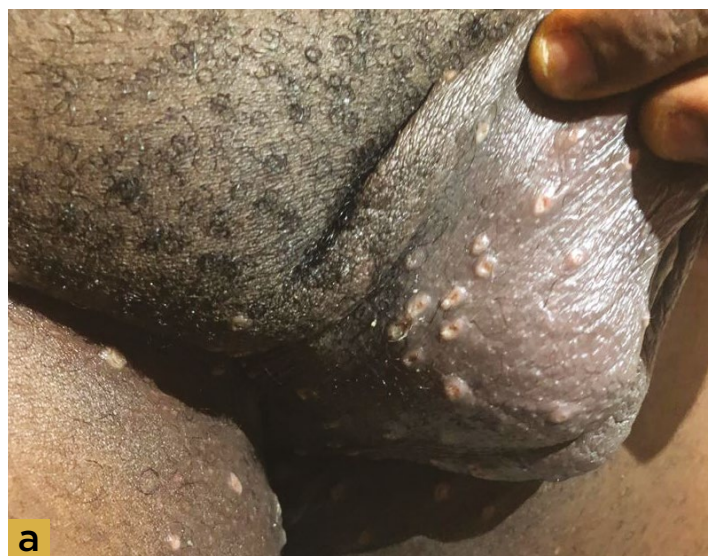PCR blood tests are not advisable as they are usually inconclusive because of the short duration of viremia relative to the timing of specimen collection after symptoms begin.<sup>6</sup> Orthopoxviruses are serologically crossreactive; therefore, antigen and antibody detection may crossreact with smallpox and cowpox, thus are unreliable.<sup>3,6</sup> Also, recent vaccination with the vaccinia vaccine (e.g. anyone recently vaccinated because of high risk, such as orthopoxvirus laboratory personnel or health workers) may lead to false-positive results.<sup>1</sup> However, in the absence of recent vaccination, serum IgM antibody to monkeypox can be useful in the management and surveillance of patients and contacts.<sup>6</sup>

A skin biopsy can be taken to exclude other differential diagnoses. The venereal disease research laboratory (VDRL) test can also be requested to exclude syphilis.<sup>6</sup> HIV screening is required for all patients as HIV infection is associated with more severe clinical disease, particularly with low CD4 count, high viral load or non-adherence to antiretroviral medications.<sup>2,6</sup>

## Differential diagnosis

It is important to identify other infections caused by viruses with a similar presentation and other non-infectious causes of a vesiculopustular rash. Below are distinguishing features of common differentials.<sup>6</sup>

- **Chickenpox (varicella zoster infection)** – early in the course of illness, lesions of monkeypox are difficult to distinguish from chickenpox. However, in chickenpox the lesions are usually at different stages and concentrated on the trunk; rarely involving the palms and soles. There is no lymphadenopathy in uncomplicated varicella zoster infection.
- **Disseminated herpes simplex** is a possible differential but the lesions in herpes are not umbilicated like in monkeypox. The Tzanck test is a rapid, inexpensive diagnostic test that involves the direct examination of fluid from a fresh vesicle (ideally <3 days old) for Tzanck cells, which are multinucleated giant cells. These cells are characteristic of herpesvirus infections, but are absent in monkeypox. It requires expertise for accurate interpretation within the clinical context.
- **Molluscum contagiosum** is a common, self-limiting condition found mainly in children, immunocompromised adults and elderly people. The lesions are small pearly papules that are firm and umbilicated. They can occur anywhere on the skin surface but are found more commonly



**Fig 6. (a) and (b)** Vesiculopustular and crusted lesions in the genital area. (Courtesy of **(a)** Dr A. O. Akinkugbe **(b)** Dr O. Cole-Adeife).

on the face, trunk, thighs and buttocks, and genital area. The lesions of molluscum, however, are not vesicular unless there is secondary infection.

- **Drug eruptions (e.g. erythema multiforme, Stevens-Johnson syndrome)** include a myriad of morphologies. They may present as raised pruritic and erythematous lesions on the extremities and trunk. They may start as small discrete papules that become confluent, larger and vesiculobullous. There can also be involvement of the oral, nasal and conjunctival mucosa.
- **Syphilis** can cause genital ulcers and palmoplantar lesions and should be excluded.
- **Dermatitis herpetiformis** is characterized by grouped excoriations, erythematous papules and vesicles, classically seen on the extensor surfaces of the elbows, knees, buttocks and back but sparing the face.
- **Eczema herpeticum** presents as monomorphic, dome-shaped clusters of itchy vesicles on an erythematous base. They often become punched out, crusted, painful ulcers.
- **Disseminated histoplasmosis** presents as polymorphic papules and plaques with or without crusts. There can also be ulcers and erosions, acneiform eruptions, erythematous papules and keratotic plaques.
- **Impetigo** causes blistering lesions found on the face, neck and upper chest in children. The blisters burst and leave honey-coloured crusts and brown patches.
- **Hand, foot and mouth disease** is an acute viral illness caused by the coxsackie virus and characterized by fever, oral and nasal mucosal ulcers as well as papulopustular lesions on the hands and feet.
- **Scabies** typically starts as small papules that may be erythematous but can also present with vesicles. They are intensely pruritic, found in web spaces, the wrists and genitals.

Careful clinical examination (including palpation of lymph nodes) and laboratory assessment are required to confirm human monkeypox infection.

## Treatment

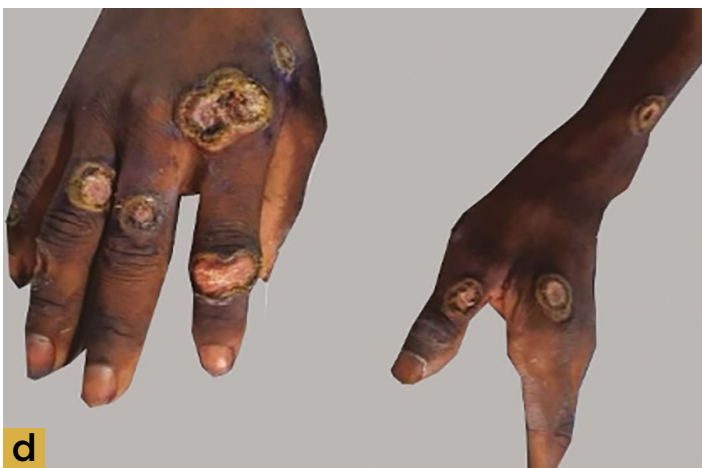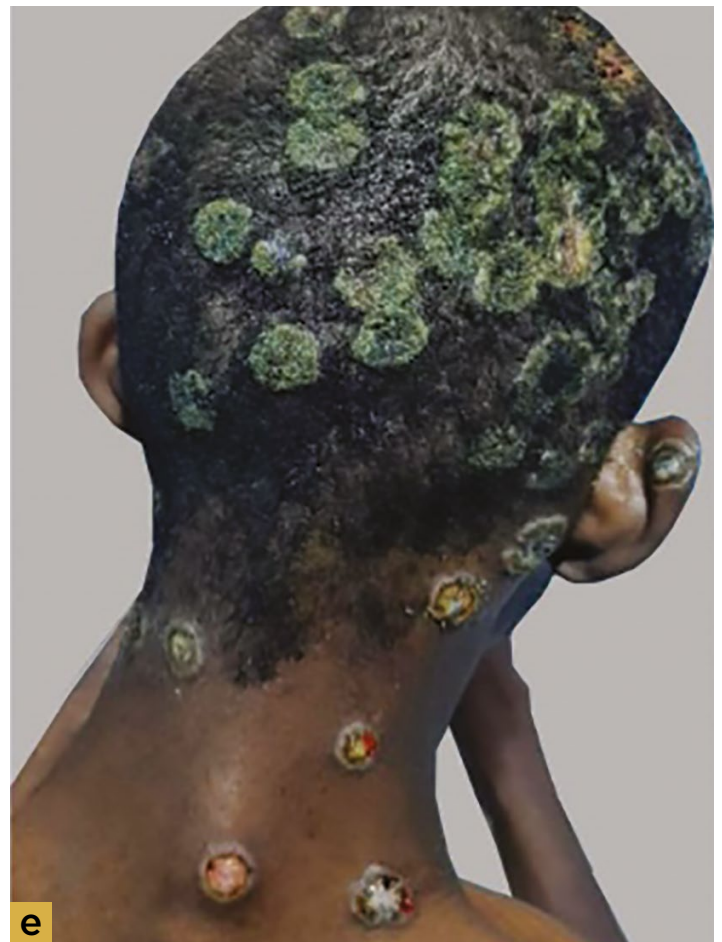
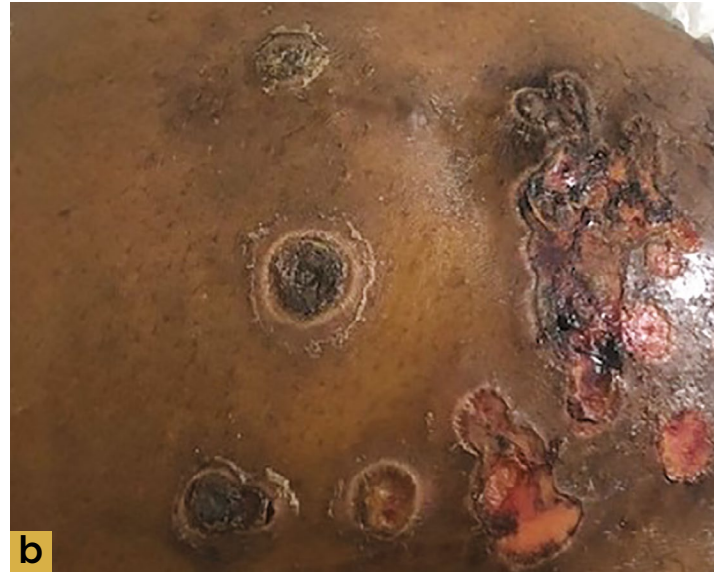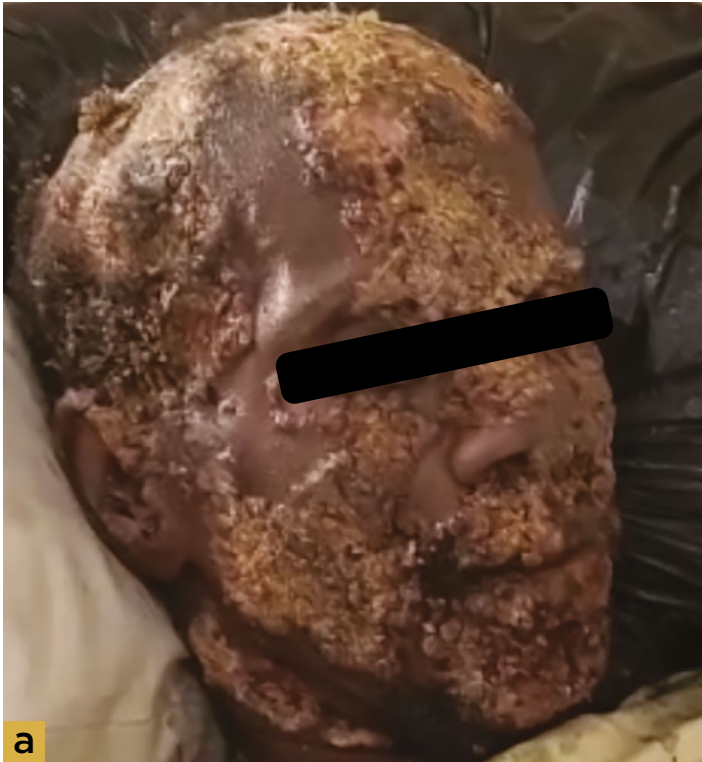Human monkeypox disease is a self-limiting condition that often resolves within 3–4 weeks.<sup>1</sup>

There are no specific treatments or vaccinations currently available for monkeypox. Some broad-spectrum antiviral agents, such as cidofovir, brincidofovir and tecovirimat, have been effective *in vitro*, but their clinical efficacy and safety profile *in vivo* are still uncertain.<sup>1,3,6</sup> Most treatment is essentially supportive. Antibiotics may be necessary if the lesions become secondarily infected by bacteria.

Patients with monkeypox should be isolated either at home or in hospital facilities, depending on severity of symptoms.<sup>6</sup> Barrier nursing with strict infection, prevention and control measures should be instituted. Contact tracing and surveillance of close contacts is essential to break the chain of transmission.<sup>1,6</sup>

Continued overleaf...





**Fig 7. (a-e)** Extensive and atypical monkeypox lesions associated with underlying immunosuppression. **(a)** Courtesy of Dr O. Cole-Adeife; **(b)** and **(c)** courtesy of Dr A. O. Akinkugbe; **(d)** and **(e)** reproduced with kind permission of Infectious Disease Unit, Lagos University Teaching Hospital.

As a result of the similarities in orthopoxviruses, the vaccinia (smallpox) vaccine is 85% effective at preventing monkeypox and childhood vaccination for smallpox has been associated with milder clinical disease.<sup>1,4</sup> The old vaccinia vaccine is no longer available, but a new third-generation vaccine has been produced and approved to prevent smallpox and monkeypox.<sup>1,10</sup> The US Centre for Disease Control and Prevention recommends pre-exposure smallpox vaccination for field investigators, veterinarians, animal-control personnel, contacts of patients with monkeypox, researchers and healthcare workers caring for patients and their contacts.<sup>10</sup> Details of currently available vaccines are

**Table 2. Available vaccines for Monkeypox disease<sup>13</sup>**

NAME	COUNTRY	TYPE OF AUTHORIZATION	CLINICAL INFORMATION	CONSIDERATIONS	PRESENTATION	INJECTION MATERIAL
<b>MVA-BN (Bavarian Nordic) 3rd generation</b>	USA Canada	Full MA (2019) Full MA (2019)	Non-replicating vaccinia-based vaccines Can be used in immune deficiencies, immunosuppression therapies, atopic dermatitis Preferred in pregnancy, breastfeeding mothers, adults ≥18 years Use in children is off label	Very limited supply Liquid-frozen formulation Approved for use in the general adult population Two doses 4 weeks apart	Liquid frozen or lyophilized (freeze-dried) Single dose vials Multidose vials possible	Needle Syringe (subcutaneous administration)
<b>ACAM20000 (Emergent BioSolutions) 2nd generation</b>	USA	EIND for PEP	Replicating vaccinia-based vaccines Contraindicated in immune deficiencies, immunosuppression therapies, atopic dermatitis Not preferred in pregnancy, breastfeeding mothers and children	Approved for use in adults aged 18–64 years Earlier production by Sanofi Pasteur approved in France	Freeze-dried Multidose vials	Bifurcated needle

provided in Table 2.<sup>11–13</sup> Early post-exposure vaccination for close contacts is recommended, ideally within 4 days of first exposure to monkeypox, to prevent the onset of disease.<sup>11</sup> These vaccines are available as stockpiles and used under guidance by respective government health agencies.

### Complications and prognosis

Most patients fully recover within 3–4 weeks without long-term scarring of the skin, depending on the degree of scratch manipulation and superimposed infections.<sup>1,6</sup> However, monkeypox has the potential to cause death, especially in young children and immunocompromised individuals.<sup>1,2,8</sup> Complications that may lead to morbidity and mortality include sepsis from secondary bacterial infection of skin lesions and also bronchopneumonia, encephalitis and corneal ulceration leading to visual loss.<sup>1,2,8</sup> The case fatality rate varies widely but is estimated to be between 1% and 10%, with most deaths occurring in children <5 years and individuals who are HIV-positive.<sup>2–4</sup> The case fatality rate is higher in the Congo Basin clade.

### Prevention and control

Prevention of monkeypox involves adequate public awareness and education on the handling of animals and the care of infected humans.<sup>1,6</sup> Infection prevention and control measures in the handling of animals and infected humans, appropriate waste disposal and adequate barrier nursing with appropriate use of personal protective equipment (PPE) are key preventive measures.<sup>1,2</sup>

Response to human monkeypox outbreaks requires early detection and effective management of patients with monkeypox and their contacts through use of a 'One Health' approach to prevent the spread of the disease.<sup>4,6</sup> Control measures, including intensive surveillance and active case finding using established standard case definitions and isolation are indispensable in the care of patients with monkeypox.<sup>4,5</sup> Risk communication and social mobilization with adequate community engagement will help in the timely breaking of the chain of transmission. A One Health approach that involves joint human environmental and animal health collaborative care has been advocated for a successful public health response to monkeypox epidemics.<sup>1,4,5</sup> This approach is multisectoral and transdisciplinary and works at local,

regional, national and global levels supporting global health security through improved collaboration, communication and coordination while addressing shared health threats. Nigeria had employed, and is still using the One Health approach in the prevention and management of the monkeypox epidemic.

### Conclusion

The skin lesions of human monkeypox virus disease are important in identifying the infection and expediting a prompt diagnosis. With global health and travel, it is important for healthcare workers to be aware and have a high index of suspicion when they see 'pox-like' lesions on the face, body and/or genitals.

The 'One-Human-Environmental-Animal-Health' effort that is a global public health strategy remains of importance given the current global attention on monkeypox and all other emerging infections.

### References

- World Health Organization. Monkeypox. Available at: <https://www.who.int/news-room/fact-sheets/detail/monkeypox> (last accessed 3 July 2022).
- Yinka-Ogunleye A, Aruna O, Dalhat M *et al*. Outbreak of human monkeypox in Nigeria in 2017–18: a clinical and epidemiological report. *Lancet Infect Dis* 2019; **19**:872–9.
- Alakunle E, Moens U, Nchinda G *et al*. Monkeypox virus in Nigeria: infection biology, epidemiology, and evolution. *Viruses* 2020; **12**:1257.
- Petersen E, Abubakar I, Ihekweazu C *et al*. Monkeypox—enhancing public health preparedness for an emerging lethal human zoonotic epidemic threat in the wake of the smallpox post-eradication era. *Int J Infect Dis* 2019; **78**:78–84.
- Durski KN, McCollum AM, Nakazawa Y *et al*. Emergence of monkeypox—West and Central Africa, 1970–2017. *Morb Mortal Wkly Rep* 2018; **67**:306–10.
- Nigeria Centre for Disease Control. National Monkeypox public health response guidelines. Available at: [https://ncdc.gov.ng/themes/common/docs/protocols/96\\_1577798337.pdf](https://ncdc.gov.ng/themes/common/docs/protocols/96_1577798337.pdf) (last accessed 3 July 2022).
- World Health Organization. Multi-country monkeypox outbreak in non-endemic countries. Available at: <https://www.who.int/emergencies/disease-outbreak-news/item/2022-DON385> (last accessed 3 July 2022).
- Ogoina D, Izebewule JH, Ogunleye A *et al*. The 2017 human monkeypox outbreak in Nigeria—report of outbreak experience and response in the Niger Delta University Teaching Hospital, Bayelsa State, Nigeria. *PLoS One* 2019; **14**:e0214229.
- Rimoin AW, Kosalu N, Kebela-Ilunga B *et al*. Endemic human monkeypox, Democratic Republic of Congo, 2001–2004. *Emerg Infect Dis* 2007; **13**:934–7.
- Centre for Disease Control and Prevention (CDC). Monkeypox. Available at: <https://www.cdc.gov/poxvirus/monkeypox/index.html> (last accessed 3 July 2022).
- Centre for Disease Control and Prevention (CDC). Smallpox/monkeypox VIS. Available at: <https://www.cdc.gov/vaccines/hcp/vis/vis-statements/smallpox-monkeypox.html> (last accessed 3 July 2022).
- Vax Before Travel. Monkeypox vaccines 2022. Available at: <https://www.vaxbeforetravel.com/monkeypox-vaccines-2022> (last accessed 3 July 2022).
- World Health Organization (WHO). Vaccines and immunization for monkeypox. Interim guidance, 14 June 2022. <https://www.who.int/publications/i/item/who-mpx-immunization-2022.1> (last accessed 6 July 2022).



# Guide to diagnosis and management of leprosy

Marlous L. Grijzen<sup>1</sup> and Ben Naafs<sup>2</sup>

<sup>1</sup>Centre for Tropical Medicine and Global Health, Nuffield Department of Medicine, University of Oxford, Oxford, UK and Eijkman-Oxford Clinical Research Unit, Jakarta, Indonesia. <sup>2</sup>Stichting Global Dermatology Munnekeburen, Friesland, the Netherlands; Regional Dermatology Training Centre (RDTC), Moshi, Tanzania; and Instituto Lauro de Souza Lima (ILSL), Bauru, Brasil.

\*Corresponding author: mgrijzen@eocru.org

**Conflict of interests:** None.

**Key words:** Leprosy, Hansen's disease, neglected tropical skin disease, multidrug therapy.

## Introduction

The claim that leprosy is no longer a public health problem (World Health Organization [WHO] 2005) is wishful thinking.<sup>1</sup> In low- and middle-income countries, patients with leprosy still present regularly at primary healthcare clinics but are often misdiagnosed and/or neglected, as leprosy services have been dismantled and specialized healthcare workers employed in other disciplines.<sup>2</sup> Similar scenarios occur in high-income countries where patients are often diagnosed too late, either because of lack of knowledge and awareness or because of self-stigma and fear of discrimination, leading to unnecessary disabilities and deformities.<sup>3</sup> Leprosy is therefore considered by the WHO as a neglected tropical skin disease.

A patient with leprosy may present with hypopigmented or erythematous macules, with nodules or plaques which are skin coloured, slightly red or hyperpigmented in dark skin. Patients may even have no visible lesions. The patients may complain of loss of sensation in the skin lesions or of the hands or feet. They may have aches and pains in the face or the limbs or mention a numb, sleepy or 'dead' sensation in the affected areas, like 'ants running under their skin'.

It is important to remember that in patients with hypopigmented, erythematous, papular or nodular lesions, the differential diagnosis should include leprosy, particularly in patients in or from endemic areas, as well as pityriasis alba, vitiligo, autoimmune diseases, neurofibromatosis, lymphoma, diabetes and bullous diseases.

## Diagnosis

Most important is awareness!! There are three cardinal signs:

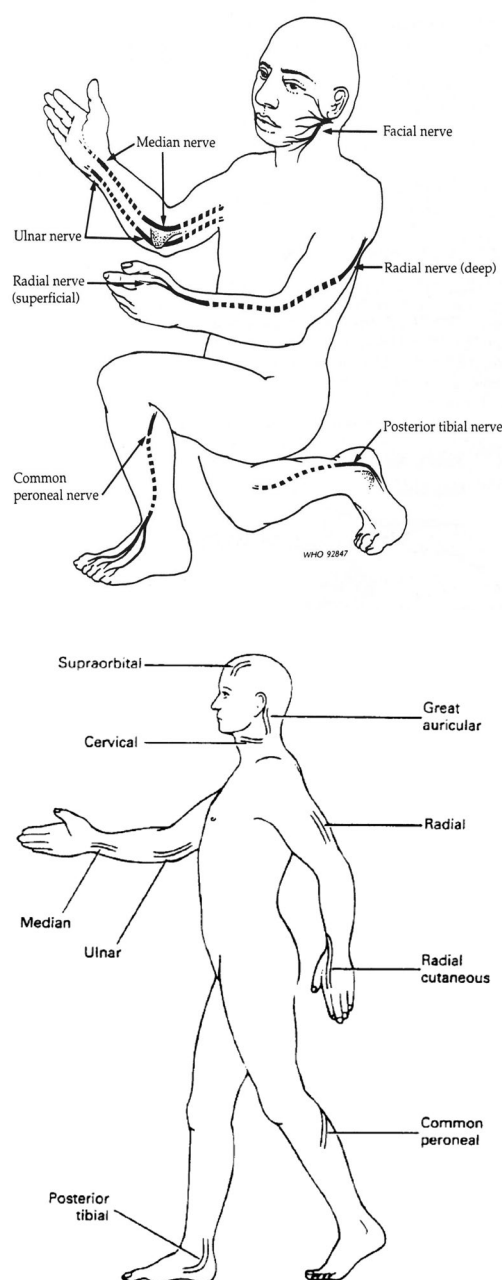
1. Loss of sensation in a skin lesion.
2. Enlarged nerves.
3. Positive slit-skin smear (SSS).

To make a definite diagnosis two out of the three cardinal signs are needed. For field settings with limited resources, one clear sign is acceptable as multidrug treatment (MDT) has minimal side-effects and outweighs the potential risk of developing future disabilities.

**Loss of sensation:** This is tested using a wisp of cotton wool. As loss of light touch is one of the first signs in leprosy, it is recommended not to use a ballpoint or a pin. The area is tested by touching, not swiping. With closed eyes the patient points where he or she is being touched. It is important to make sure the area outside the lesion is tested as well. It is useful to feel the palms of the hands and the soles of the feet for dryness because loss of sweating often presents simultaneously with loss of sensation or may even be detected earlier. Thermal

sensitivity, using hot- and cold-water tubes, may be tested as well, but seems less sensitive.

**Enlarged nerves:** these can be cutaneous nerves or subcutaneous nerves in the vicinity of skin patches or nerve trunks. Palpate at least (Figure 1):



**Fig 1.** Body diagrams highlighting the anatomical sites of the palpable peripheral nerves that are relevant to examine in clinic. Courtesy of R. Hastings and D. V. A. Opromolla.

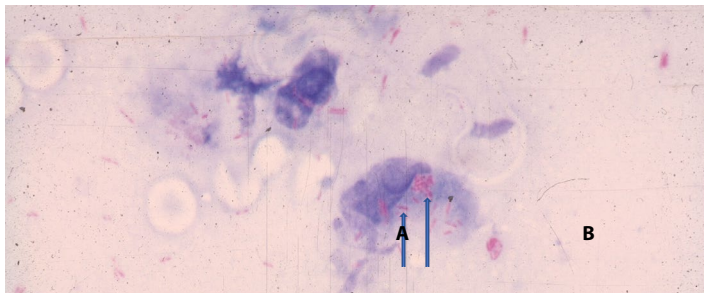


- posterior auricular nerves (branches of the facial nerve);
- ulnar nerves;
- median nerves;
- lateral popliteal nerves (also called common peroneal nerves);
- posterior tibial nerves.

You can extend to every palpable nerve. Feel for thickness, consistency and tenderness. Check for sweating, sensory and motor functions of the nerves. Ultrasound, if available, may replace palpation.<sup>4</sup> Simple ultrasound equipment is available today.

**Slit-skin smears:** These are performed to detect the infectious cause of leprosy: *Mycobacterium leprae* or *M. lepromatosis* through microscopy.<sup>5</sup> These are intracellular, acid-fast bacilli (AFB) that have a predilection for cooler areas of the body (~32°C, e.g. earlobes, chin, buttocks, elbows, knees). SSS is a rapid, relatively easy and low-cost tool to support the diagnosis of leprosy. Samples should be taken from the outer edge of the lesion in macular leprosy and from the centre of a lesion in papular leprosy. A sample from the earlobes, even when no visible lesions are present, is always useful.

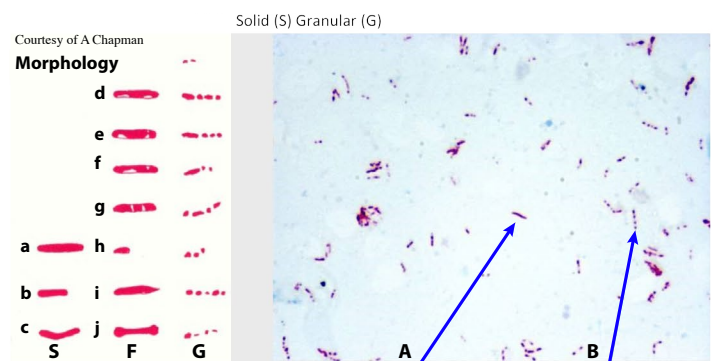
The smear is taken while squeezing the skin firmly between the thumb and index finger (or use a pincer) to numb and to diminish the bleeding. Maintain pressure and make an incision into the dermis of about 5 mm long and 2 mm deep. Only tissue fluid is required, as blood will dilute the number of bacilli in the smear (Figure 2). The bacilli are counted and graded according to a logarithmic scale (bacillary index [BI]). In addition, the percentage of solid bacteria considered



**Fig 2.** Slit-skin smear (SSS) stained for acid-fast bacilli with modified Ziehl-Neelsen. Arrows: a mycobacterium left and globus (clump of dividing bacteria) right.

living (viable) bacilli is estimated (morphological index [MI]) (Figure 3). It is important to decolorize briefly with 1% hydrochloric acid (10 seconds) in isopropyl alcohol (as in Fite-Faraco stain), as opposed to the more widely available 3% solution, used in the Ziehl-Neelsen stain for tuberculosis (TB). *Mycobacterium leprae* and *M. lepromatosis* are less acid-fast than *M. tuberculosis*, rendering the smear false-negative when using 3% hydrochloric acid. If the preferred 1% hydrochloric acid is not available, a practical answer may be to dilute the 3% solution (based on the authors' experience).

**Skin and nerve biopsy:** Histopathology can be very helpful in the diagnosis and classification of leprosy, or in the detection of leprosy reactions. It is important to take the skin biopsy from the right place: as with SSS, take the biopsy from the edge of the lesion in tuberculoid (TT) leprosy and from the centre of the lesion in lepromatous leprosy (LL) and use similar staining (Fite-Faraco). Keep in mind that a skin biopsy is taken from



**Fig 3.** The bacilli are counted and graded according to a logarithmic scale (BI, bacillary index). In addition, the percentage of solid bacteria is estimated (MI, morphological index). Morphology S: solid (live); F: fragmented (h, i, j: most likely artefacts); G: granular (dead); A: solid bacterium and B: a granular bacterium. Courtesy of A. Clapasson.

only one area of the body and may not represent the whole spectrum.

Pure neural leprosy can be diagnosed by a nerve biopsy taken from a small cutaneous or subcutaneous nerve. From a larger nerve, a fine-needle aspiration can be done for cytology and bacteriology with polymerase chain reaction (PCR).

**Laboratory tests:** These can be of help in the diagnosis and classification of leprosy. Another way to detect bacilli in a smear is through PCR. This is a more sensitive technique than the AFB staining technique,<sup>6</sup> but may still be negative in patients with paucibacillary (PB) leprosy. SSS and immunological (serology and techniques to detect cellular immunoreactivity)<sup>7</sup> and molecular (PCR) techniques are useful in the diagnosis of multibacillary (MB) leprosy, in the follow-up and in the detection of relapses.

The antibody titre against phenolic glycolipid 1 (PGL-1), a cell wall species-specific glycolipid, is a useful test in MB leprosy. However, this test may be positive in contacts and negative in PB leprosy. It helps to classify leprosy into PB and MB, and it can be used to follow the effect of treatment in patients with MB and to detect relapses.<sup>8</sup> It is extensively used in Brazil and several programmes elsewhere. The value of the recently introduced antibody test with synthetic LID-1 seems to add little additional information.

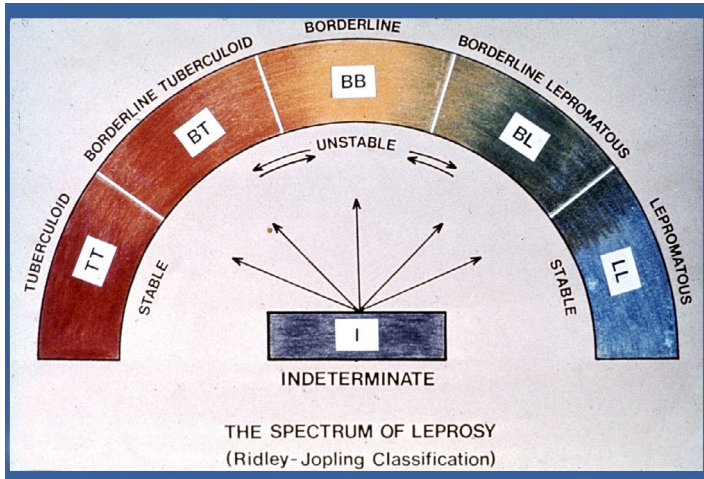
Leprosy remains a clinical diagnosis: the clinician should take everything into account, particularly the clinical symptoms, to make the diagnosis and classification.

### The clinical spectrum of leprosy is determined by the host immune response

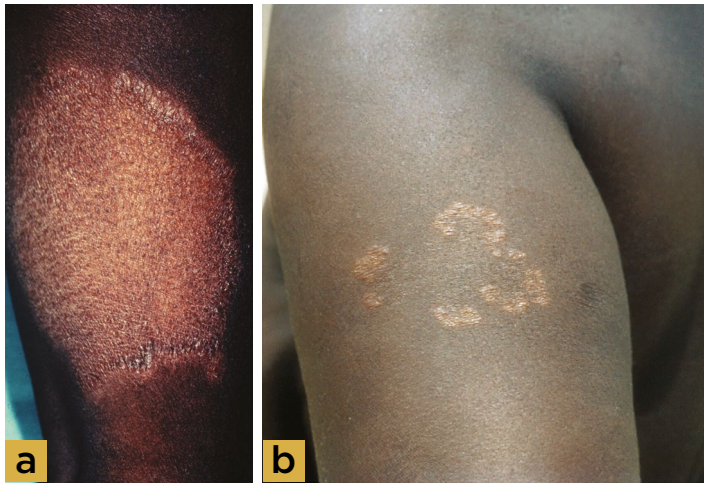It is the cell-mediated immunity (CMI) that determines the clinical spectrum of the disease in patients who develop leprosy. The Ridley-Jopling scale is useful to stratify according to CMI and to predict complications (Figure 4).<sup>9</sup> It consists of the polar tuberculoid (TT) form at one end of the spectrum (Figure 5a, b), consisting of a single well-described skin lesion or an enlarged nerve without detectable bacilli and a high CMI against *M. leprae/lepromatosis* antigenic determinants, and on the other side of the spectrum the polar lepromatous (LL)

Continued overleaf...





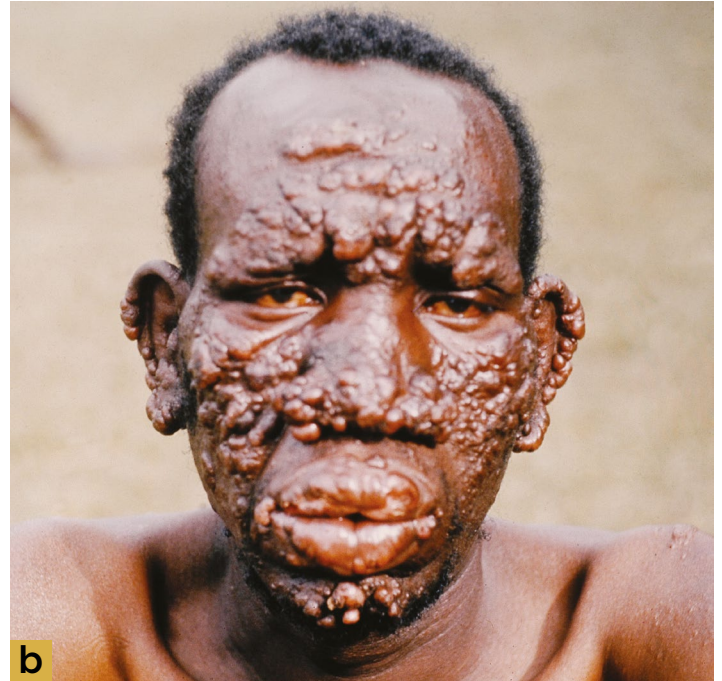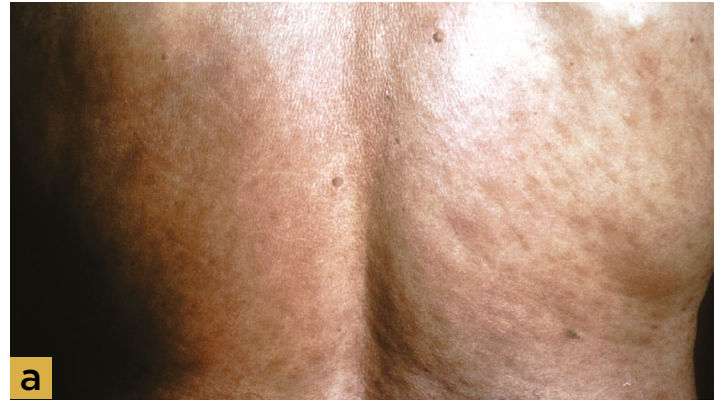**Fig 4.** Ridley-Jopling scale stratified according to cell-mediated immunity. Courtesy of D. L. Leiker.



**Fig 5.** Tuberculoid (TT) leprosy; a single well-described lesion with a healing centre. **(a)** A still slightly hypopigmented centre. **(b)** The centre heals so quickly that the rim has disappeared, and the centre stays skin coloured. **(a)** Courtesy of D. L. Leiker.

leprosy with nodules and/or plaques (Figure 6a, b), with more or less symmetrically enlarged nerves or only an infiltrated skin with numerous bacilli and a lack of CMI against *M. leprae*/*lepromatosis* antigenic determinants. *Lepra bonita* (also referred to as beautiful leprosy) is a rare form of LL leprosy in which the skin is diffusely infiltrated so that natural wrinkles disappear, and the skin becomes shiny (Figure 7). These polar groups are stable and do not change classification.

In between these polar groups are the borderline groups, comprising most patients. Patients in this group may change their classification. They may 'upgrade' (become more tuberculoid) or 'downgrade' (become more lepromatous). This may occur without many symptoms or with symptoms during a 'reaction'. Borderline tuberculoid (BT) (Figure 8) has predominantly tuberculoid features and borderline lepromatous (BL) (Figure 9a, b) has predominantly lepromatous features. Between these two types is a small group of mid-borderline (BB) leprosy (Figure 10). These patients typically have dome-shaped and/or punched-out skin lesions in which the centre is not involved. The involved border may be wavy. In some patients it is not possible to classify the



**Fig 6.** Lepromatous leprosy (LL). **(a)** Infiltrated plaques; **(b)** nodules.



**Fig 7.** *Lepra bonita*. The skin is shiny and the patient looks much younger than they are. There is hardly anything to see, only with palpation you may feel some induration.

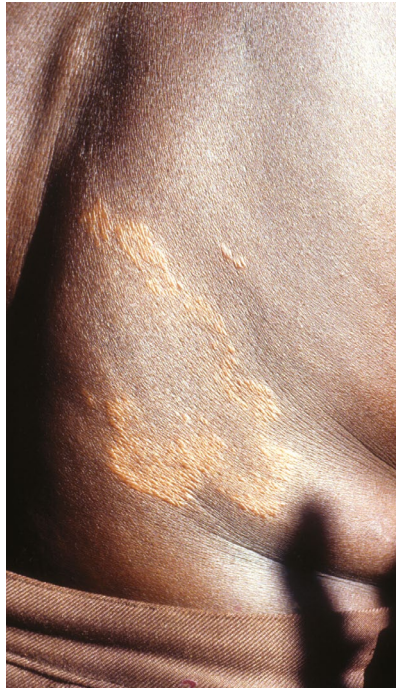type of leprosy when the lesions are clinically and histologically indeterminate (indeterminate leprosy [IL]). IL (Figure 11) is either an early stage of the disease, which usually resolves on its own, or may progress into one of the types described in the Ridley-Jopling classification, depending on the development of the CMI. Another challenging group to classify is pure neural leprosy in which there is no involvement of the skin. The frequency of this type can vary from 1% to 10%, depending on the geographical area and awareness of clinicians.

For practical purposes in the field, the WHO has



classified leprosy into two groups based on the number of skin lesions: PB leprosy includes one to five skin lesions and a negative SSS; MB leprosy is classified as six or more skin lesions, or with nerve involvement (pure neuritis, or any number of skin lesions and neuritis), or with a positive SSS irrespective of the number of lesions.<sup>8</sup> Although this is a very practical approach, several reports have shown that by just counting lesions, up to 30% of patients are incorrectly classified as PB and therefore under-treated.<sup>10</sup>

It must be emphasized that leprosy is an



**Fig 8.** Borderline tuberculoid (BT) leprosy; the rim edge is streaming and there is central healing. There are satellite lesions.

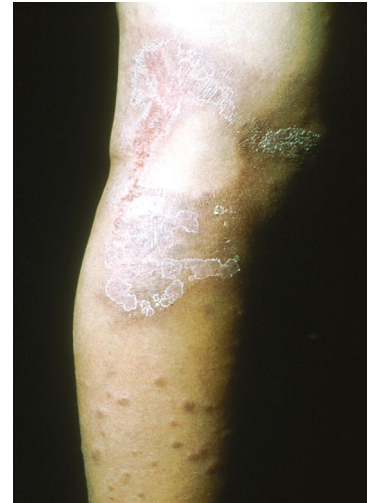infectious disease leading to an immunological disease and when not treated properly leads to deformities and disabilities.

### Treatment

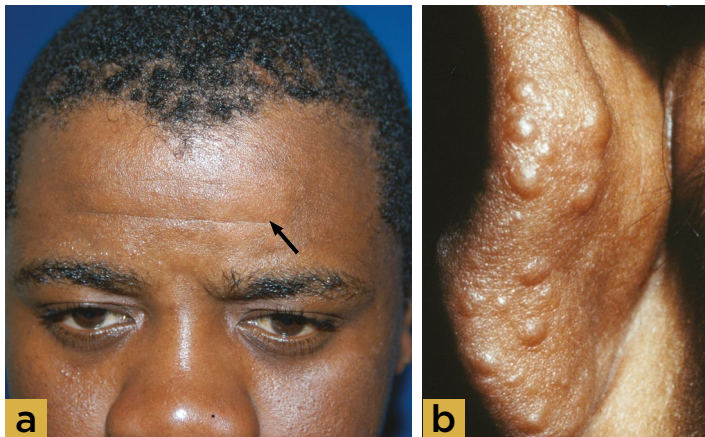MDT consists of a combination of two or three drugs depending on the type of leprosy. MDT is widely available and effective and provided free of charge through the WHO. However, monthly drug pick-ups may be a financial burden for some patients, threatening drug compliance.

**PB leprosy:** 600 mg rifampicin once monthly for 6 months under supervision and daily 100 mg dapsone, unsupervised. The dose is for a 60 kg patient. To be allowed to discontinue the treatment six supervised monthly doses should be given in 9 months (Table 1).<sup>11</sup>

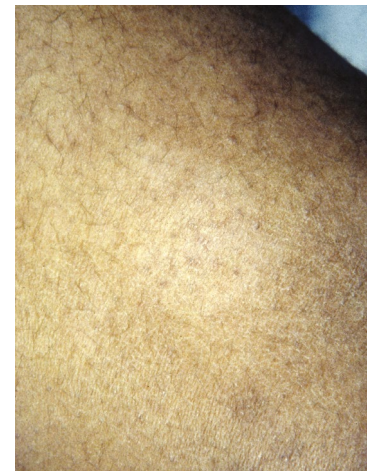**MB leprosy:** 600 mg rifampicin and 300 mg clofazimine once monthly under supervision and 100 mg dapsone and 50 mg clofazimine daily, unsupervised. The WHO guidelines advise that 12 supervised monthly doses should be given within an 18-month period.<sup>8</sup> The listed dosages are for patients weighing 60 kg or more (Table 1).



**Fig 10.** Mid-borderline (BB) leprosy. Typically round and gyrate lesions with uninvolved centre and small dome-shaped nodules. Courtesy D. L. Leiker.



**Fig 9.** Borderline lepromatous (BL) leprosy. **(a)** Minimal somewhat coppery lesions that may have loss of sensation (arrow). **(b)** Small papules in colder areas, particularly the ears.



**Fig 11.** Indeterminate leprosy. Hardly any hypopigmentation visible. There may be or may not be a minimal loss of sensation. Over time, unlike pityriasis alba, the lesions do not change place but may enlarge or resolve.

**Table 1. Multidrug treatment regimen as advised by the World Health Organization<sup>8</sup>**

Age group	Drug	Dosage and frequency	Duration (months)	
			PB	MB
Adult	Rifampicin	600mg once a month	6	12
	Dapsone	100mg daily		
	Clofazimine	300mg once a month, 50mg daily	-	
Children: 10-14 years old	Rifampicin	450mg once a month	6	12
	Dapsone	50mg daily		
	Clofazimine	150mg once a month, 50mg daily	-	
Children: <14 years old or <40 kg	Rifampicin	10mg/kg once a month	6	12
	Dapsone	2mg/kg daily		
	Clofazimine	6mg/kg once a month, 1mg/kg daily	-	

MB, multibacillary; PB, paucibacillary.

Continued overleaf...

# Guide to diagnosis and management of leprosy...continued

At present, the WHO is considering uniform MDT (UMDT), a 6-month treatment package for all leprosy classifications (PB and MB), including all three forementioned drugs. The advantage would be that in field settings a distinction in the type of leprosy is no longer needed and undertreatment is prevented. However, this strategy is questioned as many patients will unnecessarily receive clofazimine causing side-effects, e.g. hyperpigmentation that may increase stigmatization and discrimination. At the same time, UMDT is considered too short for treating MB leprosy. Patients will be at increased risk of developing reactions consequently leading to a rise in disabilities and deformities.

MDT has proved to be sturdy; the relapse rate has been very low,<sup>12</sup> although in MB leprosy, relapses may occur 6–10 years after treatment release and most studies have limited follow-up.<sup>12</sup> Overall, MDT is relatively safe and well accepted. Dapsone may cause (severe) haemolytic anaemia in patients deficient in glucose-6-phosphate dehydrogenase (G6PD).<sup>10</sup> Asian populations (e.g. China, Thailand, Nepal, Indonesia) have a higher risk of developing dapsone hypersensitivity syndrome, a drug reaction with eosinophilia and systemic symptoms (DRESS), which is associated with HLA-B\*13:01.<sup>13–15</sup> It is important to discuss the most common side-effects with patients, prior to MDT initiation.

In patients intolerant of either dapsone or clofazimine, two drugs (one of which is rifampicin) are used as in many settings alternative regimens are not available or affordable.

Alternative combinations like rifampicin, ofloxacin and minocycline (ROM) are suggested to give equivalent outcomes in the treatment of leprosy, although some studies have reported it to be less effective than MDT.<sup>16–18</sup>

**Recurrence:** After treatment the disease may recur because of undertreatment, drug resistance, persistence or new infections. In general, the recurrent episode is sensitive to the original MDT, but resistance to dapsone, rifampicin and ofloxacin has been demonstrated for which PCR testing is available.<sup>19</sup> Resistance to clofazimine is never convincingly proven. In cases of resistant *M. leprae*, depending on the type of resistance, the WHO recommends MDT with three drugs, as in Table 2, and potentially, in the future, bedaquiline.<sup>20,21</sup> Before, during and after MDT immune reactions and nerve damage may occur. These will be discussed in a follow-up paper.

## Acknowledgements

Many thanks to the patients who agreed their pictures could be used for teaching purposes.

## References

- Naafs B. Viewpoint: leprosy after the year 2000. *Trop Med Int Health* 2000; **5**:400–3.
- da Costa Nery JA, Schreuder PA, de Mattos PC *et al.* Hansen's disease in a general hospital: uncommon presentations and delay in diagnosis. *J Eur Acad Dermatol Venereol* 2009; **23**:150–6.
- Lockwood DN, Reid AJ. The diagnosis of leprosy is delayed in the United Kingdom. *QJM* 2001; **94**:207–12.
- Jain S, Visser LH, Suneetha S. Imaging techniques in leprosy clinics. *Clin Dermatol* 2016; **34**:70–8.
- [No authors listed.] WHO guidelines for skin smears. *Int J Lepr Other Mycobact Dis* 1987; **55**:421–2. [http://ijl.ilsl.br/detalhe\\_artigo.php?id=MTcwOQ%3D%3D&secao=WHO+GUIDELINES+FOR+SKIN+SMEARS](http://ijl.ilsl.br/detalhe_artigo.php?id=MTcwOQ%3D%3D&secao=WHO+GUIDELINES+FOR+SKIN+SMEARS)
- Mohanty PS, Naaz F, Bansal AK *et al.* Molecular detection of *Mycobacterium leprae* using RLEP-PCR in post elimination era of leprosy. *Mol Biol Res Commun* 2020; **9**:17–22.
- de Souza VN, Iyer AM, Lammas DA *et al.* Advances in leprosy immunology and the field application: a gap to bridge. *Clin Dermatol* 2016; **34**:82–95.
- World Health Organization. Guidelines for the diagnosis, treatment and prevention of leprosy. Available at: <https://apps.who.int/iris/bitstream/handle/10665/274127/9789290226383-eng.pdf> (last accessed 11 July 2022).
- Ridley DS, Jopling WH. Classification of leprosy according to immunity. A five-group system. *Int J Lepr Other Mycobact Dis* 1966; **34**:255–73.
- Alemu Belachew W, Naafs B. Position statement: LEPROSY: diagnosis, treatment, and follow-up. *J Eur Acad Dermatol Venereol* 2019 Jul; **33**:1205–13.
- Gelber RH, Grosset J. The chemotherapy of leprosy: an interpretive history. *Lepr Rev* 2012; **83**:221–40.
- Lockwood DNJ, Butlin CR, Penna GO. Current leprosy multi-drug treatment duration for MB patients (12 months) produces good clinical outcomes over many years; *Lepr Rev* 2021; **92**:97–101.
- Krismawati H, Irwanto A, Pongtiku A *et al.* Validation study of HLA-B\*13:01 as a biomarker of dapsone hypersensitivity syndrome in leprosy patients in Indonesia. *PLoS Negl Trop Dis* 2020; **14**:e0008746.
- Wang N, Parimi L, Liu H, Zhang F. A review on dapsone hypersensitivity syndrome among Chinese patients with an emphasis on preventing adverse drug reactions with genetic testing. *Am J Trop Med Hyg* 2017; **96**:1014–18.
- Zhang F-R, Liu H, Irwanto A *et al.* HLA-B\*13:01 and the dapsone hypersensitivity syndrome. *N Engl J Med* 2013; **369**:1620–8.
- Lazo-Porrás M, Prutsky GJ, Barrionuevo P *et al.* World Health Organization (WHO) antibiotic regimen against other regimens for the treatment of leprosy: a systematic review and meta-analysis. *BMC Infect Dis* 2020; **20**:62.
- Lockwood DNJ, Da Graca Cunha M. Developing new MDT regimens for MB patients; time to test ROM 12 month regimens globally. *Lepr Rev* 2012; **83**:241–4.
- Setia MS, Shinde SS, Jerajani HR, Boivin JF. Is there a role for rifampicin, ofloxacin and minocycline (ROM) in the treatment of leprosy? Systemic review and meta-analysis. *Trop Med Int Health* 2011; **16**:1541–51.
- Araujo S, Goulart LR, Truman RW *et al.* qPCR-High resolution melt analysis for drug susceptibility testing of *Mycobacterium leprae* directly from clinical specimens of leprosy patients. *PLoS Negl Trop Dis* 2017; **11**:e0005506.
- ClinicalTrials.gov. A study to evaluate the efficacy and safety of bedaquiline (TMC207) in participants with multibacillary leprosy. Available at: <https://www.clinicaltrials.gov/ct2/show/NCT03384641?cond=Leprosy&rank=10> (last accessed 11 July 2022).
- Ji B, Chaffour A, Andries K, Jarlier V. Bactericidal activities of R207910 and other newer antimicrobial agents against *Mycobacterium leprae* in mice. *Antimicrob Agents Chemother* 2006; **50**:1558–60.

**Table 2. Alternative regimens in case of drug resistance to rifampicin and rifampicin plus ofloxacin according to World Health Organization guidelines**

Resistance type	Drug alternatives	
	First 6 months (daily)	Next 18 months (daily)
Rifampicin resistance	Levofloxacin 500mg + minocycline 100mg + clofazimine 50mg	Levofloxacin 500mg OR minocycline 100mg + clofazimine 50mg
	Levofloxacin 500mg + minocycline 500mg + clofazimine 50mg	Levofloxacin 500mg + clofazimine 50mg
Rifampicin plus ofloxacin resistance	Clarithromycin 500mg + minocycline 100mg + clofazimine 50mg	Clarithromycin 500mg OR minocycline 100mg + clofazimine 50mg

Of note. Levofloxacin 500 mg, ofloxacin 400 mg and moxifloxacin 400 mg may be interchanged depending on resistance profiles and availability.



## Treatment of pyogenic granuloma with salt therapy: an effective approach

Ruth Lawless\* and Anna Ascott

University Hospitals Sussex, Worthing, West Sussex, BN11 2DH.

\*Corresponding author: ruth.lawless@nhs.net

**Conflict of interests:** None.

**Funding sources:** None.

Pyogenic granulomas (PG) are benign rapidly growing vascular lesions, usually appearing as solitary red-brown fleshy nodules that bleed easily. PGs are most commonly found on acral surfaces (such as fingers) and on the face, but they can occur anywhere, including in mucosal sites. They are often found in children at sites of minor trauma, or during pregnancy. PG can cause significant morbidity because of recurrent bleeding. Potential treatment modalities include curettage and cautery, and cryotherapy, but they often lead to scarring and the rate of recurrence is high. Surgical excision is a definitive approach but can be difficult to access. Several cases in the literature have proposed salt therapy as a cheap, accessible, low-cost and effective treatment. Its mechanism of action may be that salt creates a hyperosmolar environment, drying and shrinking the central vessel that drives the lesion.

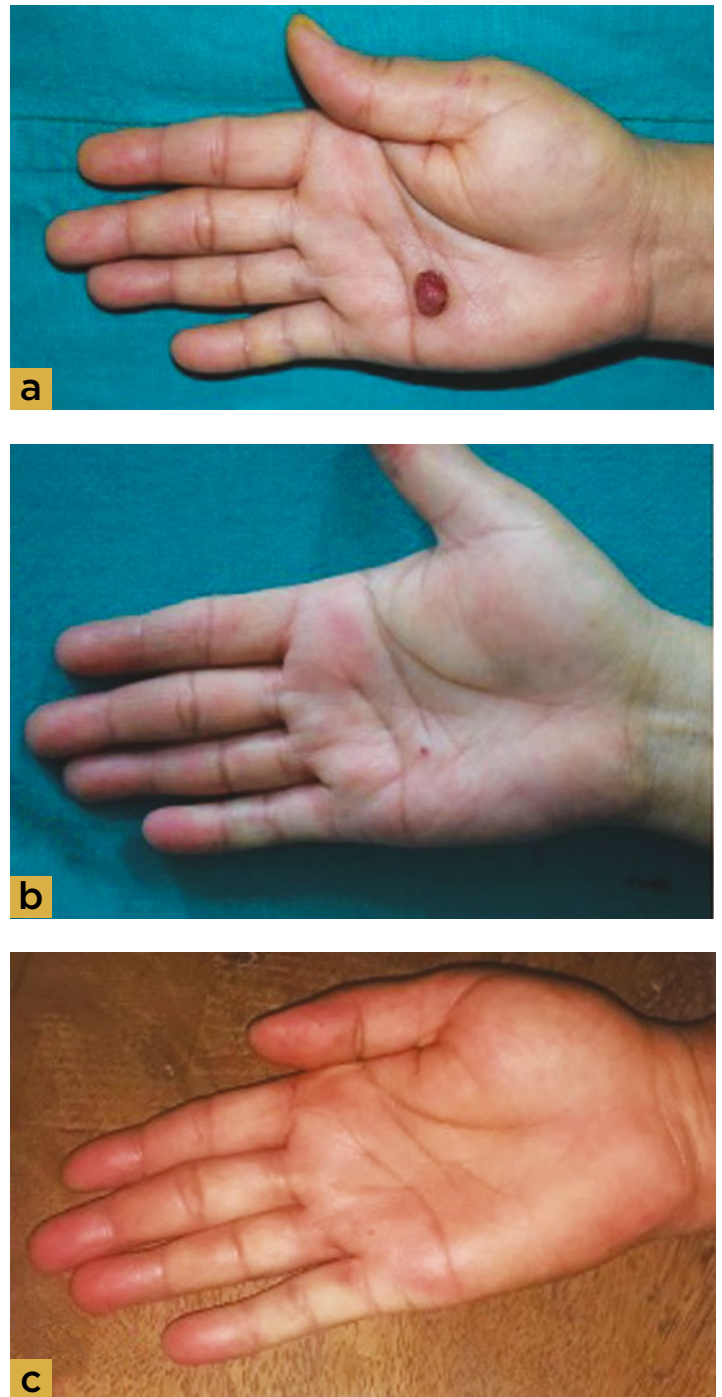
The largest case series of salt treatment for PG was reported by Daruwalla *et al.*, studying 50 patients in India.<sup>1</sup> A simple emollient, such as white soft paraffin, was applied to protect normal surrounding skin. Sufficient salt to cover the lesion was then applied. For smaller lesions, the cap of an insulin syringe was filled with salt to act as a reservoir, and then placed over the lesion. Surgical adhesive tape was then applied to secure the salt. This process was repeated daily until the PG had disappeared (Figure 1). For lip or genital lesions, if the salt became wet, it was removed and reapplied. Complete resolution was seen in all cases, without scarring. PGs on mucosal surfaces were faster to resolve than those on skin (mean resolution time 10 vs. 18.3 days, respectively). In this case series, only one case of PG on the scalp recurred after 11 months. Some patients reported a burning sensation during salt application, but the treatment was generally well tolerated.

There are several possible differentials of PG to consider before initiating treatment, including bacillary angiomatosis, Kaposi sarcoma and amelanotic melanoma. Bacillary angiomatosis normally presents with multiple red nodules, in patients who are immunocompromised, particularly with HIV. Kaposi sarcoma usually presents with more than one macule or nodule and it is less likely to bleed. Amelanotic melanoma can look very similar to PG, but has a very poor prognosis, and would not respond to salt therapy.

In conclusion, salt therapy can be an effective, accessible and safe treatment for PG resulting in resolution without scarring.

### Reference

1. Daruwalla SB, Ghate S, Dhurat R. Establishing the efficacy and safety of the novel use of common salt for the treatment of pyogenic granuloma. *Clin Exp Dermatol* 2021; **46**:1243–7.



**Fig 1.** (a) Pyogenic granuloma on the right palm; (b) near-complete resolution after 28 days of salt application with a small nidus remaining; (c) complete resolution with no residual scar after 35 days of salt application. (Courtesy of Dr Daruwalla *et al.*, and the Editor, *Clin Exp Dermatol*)

# A typical clinical presentation of dermatophytosis in a child: a reflection of topical steroid misuse

Durga Satheesh\* and Ramesha M. Bhat

Department of Dermatology Venereology and Leprosy, Father Muller Medical College, Mangalore, India.

\*Corresponding author: durgasatheesh@gmail.com

**Conflict of interests:** None.

**Funding sources:** None.

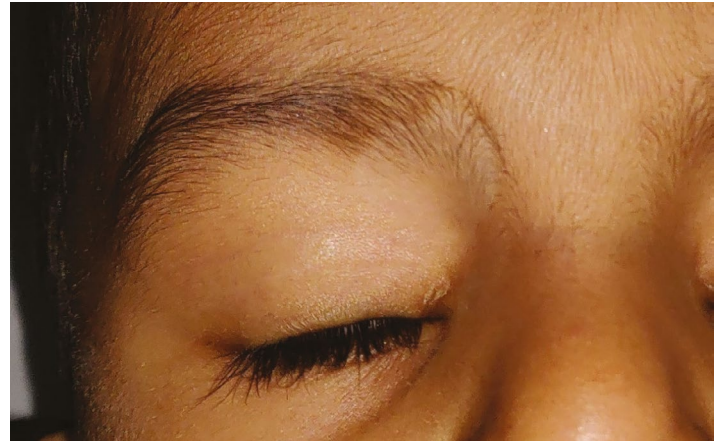**Key words:** Dermatophytosis, fungal infection, skin, topical corticosteroids, tinea incognito, antifungals.

## Introduction

Dermatophytosis is one of the most predominant skin infections in India. The prevalence of dermatophytosis is about 13% in India and about 20–25% in the world.<sup>1,2</sup> It is caused by the three genera *Microsporum*, *Trichophyton* and *Epidermophyton*. Various factors like standard of living, hygiene, environmental temperature and humidity will influence the pattern of disease.<sup>3</sup> Although the disease is not life-threatening, it can cause discomfort and distress. Treatment is usually started without any laboratory investigations and without identifying the underlying organism.<sup>4</sup> In India there is an increased prevalence of tinea in children, including infants, although it is less frequent than in adults. The treatment of dermatophytosis in children is usually limited to topical antifungals. This might be because of rapid turnover of skin leading to better clinical response to topicals compared with adults.<sup>5</sup> Treatment of dermatophytosis has become a problem; because of a large number of freely available topical combinations of steroids with other drugs, dermatophytosis has not only become a common recurrent disease but also a chronic and recalcitrant one.

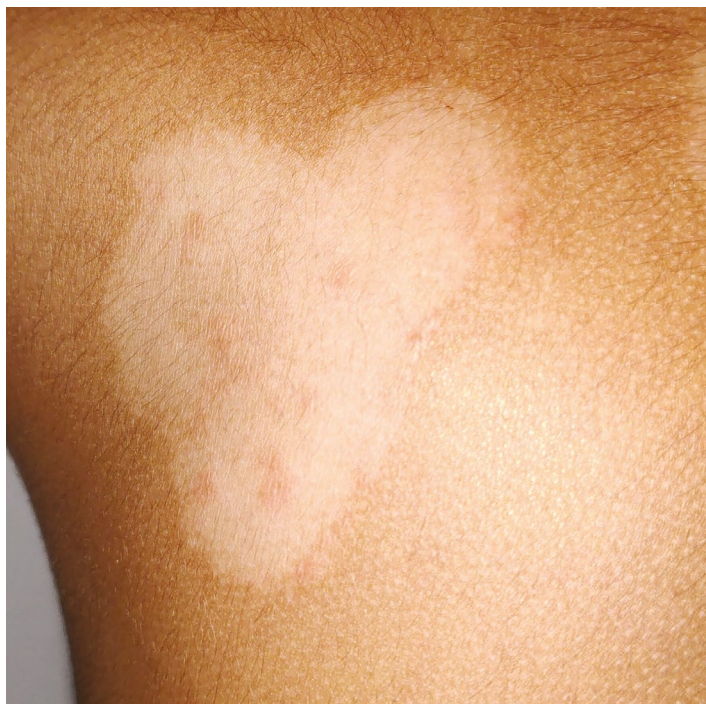## Case presentation

A 20-month-old Indian male, in good health with no history of fever or malnutrition presented to our outpatient department with multiple pruritic, hypopigmented to depigmented

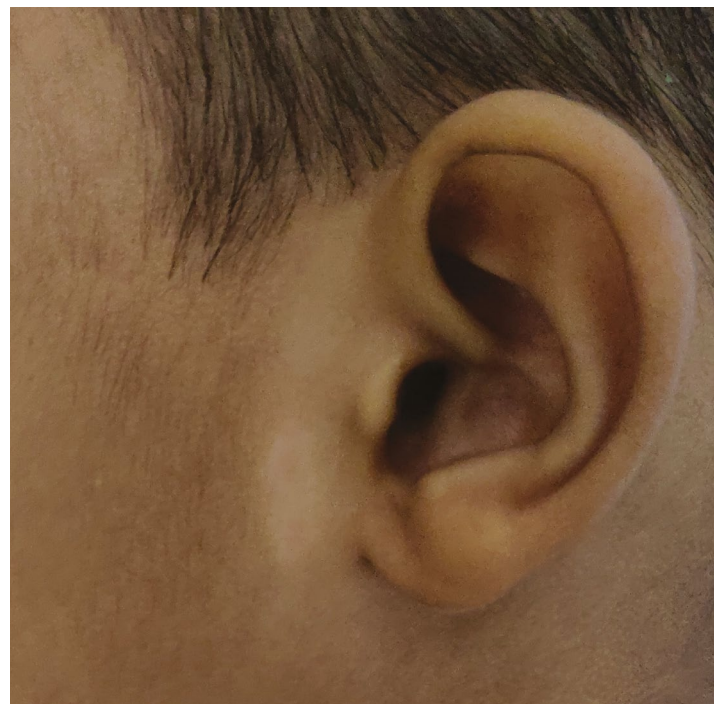

**Fig 2.** Hypopigmented well-demarcated macule over right eyebrow.

macules over the trunk and face. On further questioning, his mother mentioned that the lesions were initially erythematous and pruritic. There was a similar history in other family members 4 months previously. He was not in contact with any pets or animals. The family belonged to a low socioeconomic background. They lived in a house with two bedrooms and it was overcrowded with nine residents, including three children.

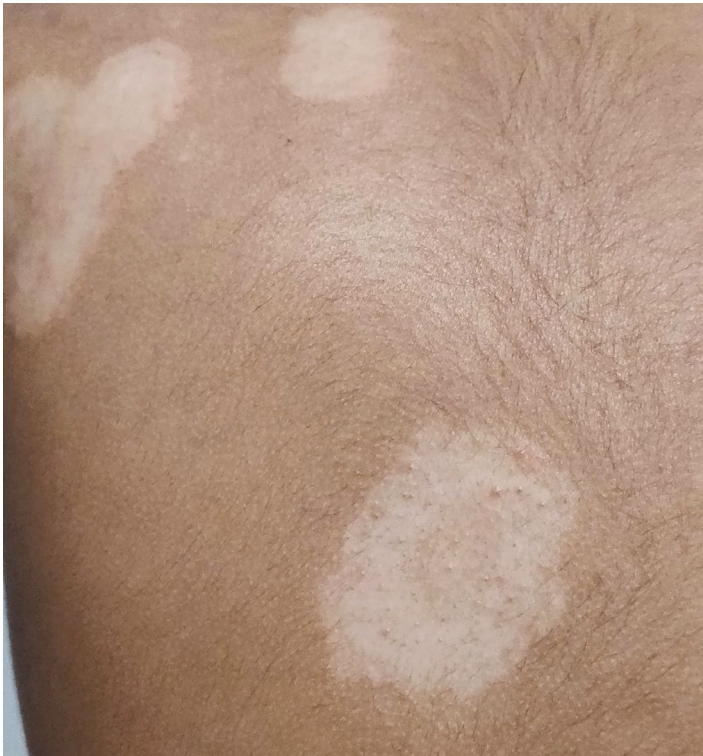

**Fig 1.** Hypopigmented macule with few erythematous papules scattered over the lesion.



**Fig 3.** Hypopigmented macules coalesced to form a dumb-bell pattern over the pre-auricular area.





**Fig 4.** Hypopigmented macule with central normal pigmentation and multiple scattered papules.

Further clinical examination revealed minute erythematous papules overlying hypopigmented macules, along with minimal scaling (Figures 1–4). The sensation over the lesions was normal and there was no nerve enlargement, hence leprosy, which is common in this part of the world, was excluded. There were no systemic symptoms.

On further enquiry the mother revealed that she had applied an over-the-counter topical medication, containing clobetasol propionate, miconazole nitrate and neomycin sulphate to the lesions continuously over 3 months.

A potassium hydroxide mount showed the presence of fungal hyphae, but the fungal culture turned out to be negative, perhaps because of prior treatment.

## Discussion and conclusion

There is a rising prevalence of dermatophytosis in tropical countries.<sup>2</sup> Various factors such as overcrowding (as in this

case), poor hygiene and climatic changes contribute to infection. Additionally, freely available topical corticosteroids present a major challenge for treating dermatophytosis. Various studies have reported the use of over-the-counter drugs, which are sold by pharmacists and chemists.<sup>6</sup> Recently, creams containing corticosteroids have been included in the Schedule H (prescription only) drugs in India, following the sustained efforts of the Indian Association of Dermatologists, Venereologists and Leprologists (IADVL) with support from The International League of Dermatological Societies (ILDS). Similarly, an unpublished study of 174 cases of tinea infection in our institute showed that clobetasol (as opposed to hydrocortisone or betamethasone) was the most commonly used topical steroid in fixed-dose combination, as its use is not controlled. This combination, if used in children, can result in atypical morphology (such as arciform, linear or tinea pseudoimbricata) and it will become resistant to treatment. Recently, Panda and Verma have compared 'tinea incognito' and 'steroid-modified tinea' and concluded that topical steroids modify the morphology of tinea to varying extent but do not necessarily make the disease difficult to recognize, therefore most of them are better described as steroid-modified tinea rather than tinea incognito.<sup>7</sup>

Treatment of dermatophytosis should comprise plain topical antifungals such as ketoconazole, luliconazole, sertaconazole, eberconazole or terbinafine and, if required, oral antifungals such as terbinafine, itraconazole, fluconazole and sometimes griseofulvin for a period of 4–8 weeks. The irrational use of combination creams containing high-potency steroids is considered one among the reasons for the current menace of dermatophytosis.

## References

1. Sudha M, Ramani CP, Heber Anandan. Prevalence of dermatophytosis in patients in a tertiary care centre. *Int J Contemp Med Res* 2016; **3**:2399–401.
2. Havlickova B, Czaika VA, Friedrich M. Epidemiological trends in skin mycoses worldwide. *Mycoses* 2008; **51** (Suppl):2–15.
3. Shenoy MM, Shenoy SM. Superficial fungal infections. In: *IADVL Textbook of Dermatology* (Saccidanand S, ed), 4th edn. Mumbai: Bhalani Publishing House, 2015; 459–513.
4. Maulingkar SV, Pinto MJ, Rodrigues S. A clinico-mycological study of dermatophytoses in Goa, India. *Mycopathologia* 2014; **178**:297–301.
5. Kaul S, Yadav S, Dogra S. Treatment of dermatophytosis in elderly, children, and pregnant women. *Indian Dermatol Online J* 2017; **8**:310–18.
6. Dabas R, Janney MS, Subramaniam R *et al*. Use of over-the-counter topical medications in dermatophytosis: a cross-sectional, single-centre, pilot study from a tertiary care hospital. *Indian J Drugs Dermatol* 2018; **4**:13–17.
7. Panda S, Verma S. The menace of dermatophytosis in India: the evidence that we need. *Indian J Dermatol Venereol Leprol* 2017; **83**:281–4.

## WORLD CONGRESS OF DERMATOLOGY Singapore 3-8 July 2023

For details of WCD call for abstracts, including list of topics etc:

<https://www.wcd2023singapore.org/scientific-programme/abstract-submission/>

Llink for WCD Scholarships:

<https://www.wcd2023singapore.org/scientific-programme/scholarships/>

The closing date for applications is 24th September 2022.

## Share Your Stories

We would love to hear how healthcare workers are using the CSH journal to support the delivery of skin health services around the world. We welcome you to share your experiences of using the journal with us. These case studies will be featured in future editions.

Please send us your stories by email at [CSH@ilds.org](mailto:CSH@ilds.org) or tag us on Twitter, Instagram, or Facebook at @IFDerm.

## Editors

Chris Lovell (UK), Michele Murdoch (UK)

## Founding Editor

Paul Buxton (UK)

## Editorial Secretary

ILDS Secretariat

## Editorial Board

Ayesha Akinkugbe (Nigeria)  
Anna Ascott (UK)  
Susannah Baron (UK)  
Workalemahu A. Belachew (Ethiopia)  
Jean Bolognia (USA)  
Isabel Casas (Argentina)  
David Chandler (UK)  
Steve Ersser (UK)  
Guadalupe Estrada (Mexico)  
Claire Fuller (UK)

Chris Griffiths (UK)  
Henning Grossman (Germany)  
Rod Hay (UK)  
Sarah Hogan (UK)  
Arjan Hogewoning (Netherlands)  
Vineet Kaur (India)  
Harvey Lui (Canada)  
Deepani Munidasa (Sri Lanka)  
John Masenga (Tanzania)  
Rachael Morris-Jones (UK)

Anisa Mosam (South Africa)  
Kelvin Mponda (Malawi)  
Ben Naafs (Netherlands)  
Rebecca Penzer-Hick (UK)  
Rune Philemon (Tanzania)  
Terence Ryan (UK)  
Mafalda Soto (Spain)  
Gail Todd (South Africa)  
Shyam Verma (India)  
Steve Walker (UK)

## How to receive the Community Skin Health journal

The Community Skin Health journal (CSH) is available in digital and hard copy.

It is **free** to subscribe to either the digital or paper issue: please visit:

<https://ilds.org/our-foundation/community-skin-health-journal/>

You can also **download** the CSH App for your phone or tablet on Android & iOS.

## Write an article

If you have an interest in dermatological healthcare the CSH is a great opportunity to share your experience by sending articles, reports and letters. Please visit the CSH website for the Guidelines for Authors.

Please send your submission by email to [CSH@ILDS.org](mailto:CSH@ILDS.org) or by post to Community Skin Health, International Foundation for Dermatology, Willan House, 4 Fitzroy Square, London W1T 5HQ, UK

## Copyright

Articles may be photocopied, reproduced or translated provided these are not used for commercial or personal profit. Acknowledgements should be made to the author(s) and to Community Skin Health.

## Publisher

Community Skin Health is published by the International League of Dermatological Societies (ILDS) as the official journal of the International Foundation for Dermatology (IFD) <https://ilds.org/>

## Disclaimer

The Publisher, International League of Dermatological Societies and Editors cannot be held responsible for errors or consequences arising from the use of information contained in the journal. The views and opinions expressed do not necessarily reflect those of the Publisher, International League of Dermatological Societies and Editors, neither do the advertisements constitute any endorsement by the Publisher, International League of Dermatological Societies and Editors.

ISSN 2632-8046



Officially founded in 1935, the International League of Dermatological Societies (ILDS) has been promoting skin health around the world for over 80 years. Its forerunner began in 1889 at the first of many World Congresses of Dermatology. Today, the ILDS represents dermatology at the highest level with over 170 members from more than 80 countries; we represent over 200,000 dermatologists.

The International Foundation for Dermatology (IFD) was created in 1987 to carry out the global health dermatology activities of the ILDS. Today, the IFD supports projects in Africa, AsiaPacific and South America. CSH is the official journal of the IFD.



Allied to HIFA  
Health information for All

## Become a CSH Friend

For just \$5, £5 or €5 a month you can become a CSH Friend. Your regular donation will help us send over 10,000 copies of the journal to healthcare workers around the world.

For more information on becoming a Friend email

[CSH@ILDS.org](mailto:CSH@ILDS.org)



If you shop online, you can support the journal financially at no extra cost. Several major retailers will make a donation based on the amount you spend.

[www.easyfundraising.org.uk](http://www.easyfundraising.org.uk)

Promoting global  
**Community Skin Health**  
through education